

<https://doi.org/10.5327/2525-5711.432>

Case Report

USE OF CAD/CAM TECHNOLOGY IN THE TREATMENT OF AMELOBLASTOMA: A CASE REPORT

Willian Gabriell de Matos Araújo Moraes (<https://orcid.org/0000-0002-5545-1795>)¹

Corresponding author,

Arianne Kimberly Barbosa da Matta (<https://orcid.org/0000-0003-0039-9560>)²

Marco Túllio Becheleni Ávila Guimarães (<https://orcid.org/0000-0003-2576-3680>)¹

Wagner Henriques de Castro (<https://orcid.org/0000-0003-2745-2878>)^{1,3}

¹ Hospital das Clínicas da Universidade Federal de Minas Gerais, Belo Horizonte, Minas Gerais, Brasil;

² Faculdade de Odontologia de Ribeirão Preto da Universidade de São Paulo, Ribeirão Preto, São Paulo, Brasil;

³ Faculdade de Odontologia da Universidade Federal de Minas Gerais, Belo Horizonte, Minas Gerais, Brasil.

Correspondence to: Address: Alameda Vereador Álvaro Celso, 250, apt 208. Santa Efigênia, Belo Horizonte, Minas Gerais- CEP 30150260

Cellphone: +55 (79)998914684

E-mail: willgabriell@hotmail.com

Received on October 13, 2025. Accepted on March 9, 2026.

Abstract:

Ameloblastoma is the most common benign epithelial odontogenic tumor, although it is aggressive and locally invasive, and its treatment frequently results in mandibular defects requiring complex reconstruction. This case report describes a secondary mandibular reconstruction using an iliac crest graft (ICG) assisted by Computed-Aided Design and Computed-Aided Manufacturing (CAD–CAM) technology. A 28-year-old female who was diagnosed with Ameloblastoma in the mandibular region underwent segmental mandibular resection followed by delayed reconstruction planned through virtual surgical planning, mandibular mirroring, and fabrication of patient-specific cutting guides and stereolithographic models. The CAD–CAM workflow enabled accurate graft harvesting and adaptation, and reduced operative time, enhancing surgical predictability and minimizing morbidity. The patient subsequently achieved satisfactory functional and aesthetic rehabilitation and remains under long-term follow-up without recurrence. This report highlights the applicability of CAD–CAM as a reliable and precise strategy for mandibular reconstruction after tumor resection.

Keywords: Ameloblastoma; CAD–CAM; Mandibular reconstruction.

Statement of Clinical Significance

This case demonstrates a successful multi-stage protocol for Ameloblastoma treatment, validating CAD/CAM-assisted secondary mandibular reconstruction with iliac crest graft. Digital planning improved surgical precision, enabling predictable implant-supported rehabilitation and a reliable workflow for managing complex mandibular defects.

Introduction:

Ameloblastoma is the most frequent benign epithelial odontogenic tumor¹, but aggressive and locally invasive, commonly involving the posterior mandible site. In most cases this tumour presents as a painless swelling of the mandible associated or not with tooth displacement. Although surgery is the most used treatment for Ameloblastoma^{1,2}, there is ongoing debate regarding the most appropriate approach, ranging from conservative to radical techniques¹. Several reconstructions modalities are proposed to the mandible defects considering size and anatomical site^{3,4}.

While the fibula free flap (FFF) remains the standard after mandibular resection^{5,6}, the iliac crest graft (ICG) represents an effective donor site option for reconstruction. The choice between FFF and ICG is influenced by factors such as donor-site morbidity, graft height and length, resorption rate, prosthetic rehabilitation complexity, and defect size^{3,4}.

Computed-Aided Design and Computed-Aided Manufacturing (CAD–CAM) technology have been introduced in orofacial reconstruction to increase precision and to reduce morbidity and operative time. This technology allows preoperative planning of the resection, fabrication of surgical guides, and pre-shaping of the reconstructive bone plate based on the native mandibular anatomy or stereolithographic models that mirror the healthy cortical bone when necessary. However, its use is limited by high cost and by reduced adaptability when intraoperative surgical planning changes⁷.

This case report highlights the reliability and predictability of CAD–CAM in secondary mandibular reconstruction using an iliac crest graft with long-term follow-up.

Case Report

A 28-years-old female patient attended to the Oral Medicine Service, School of Dentistry, Universidade Federal Minas Gerais, Brazil, with a slight swelling in the posterior right mandible site with an indeterminate evolution time, with painful symptoms in the mandible base close to the second molar of the same side. In the anamnesis, the patient denied comorbidities and medicine allergies; and use of contraceptive medication only. Extraoral examination showed a facial asymmetry located in the right masseter region. Intraoral examination revealed no significant clinical findings (Figure 1).

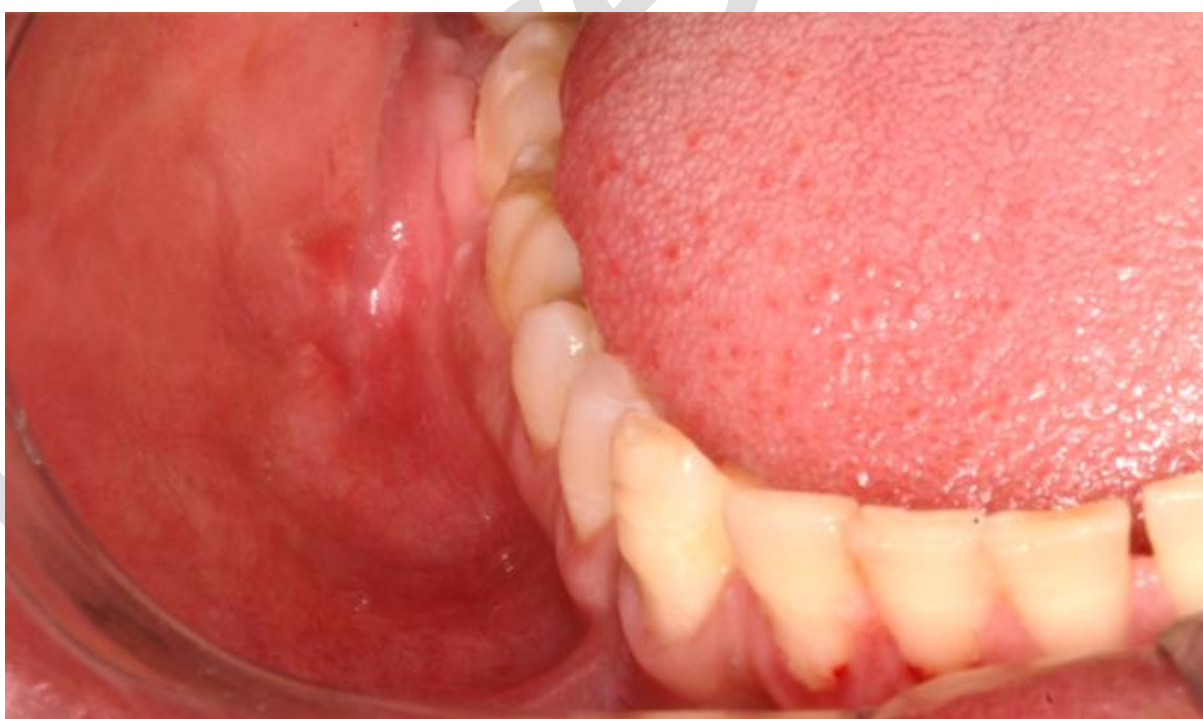

Figure 1. Inicial intraoral image.

A computed tomography (CT) scan revealed an extensive hypodense lesion, multiloculated, well-defined and with lingual cortical expansion associated with the right mandible molars. Moreover, root resorption was observed (Figure 2).

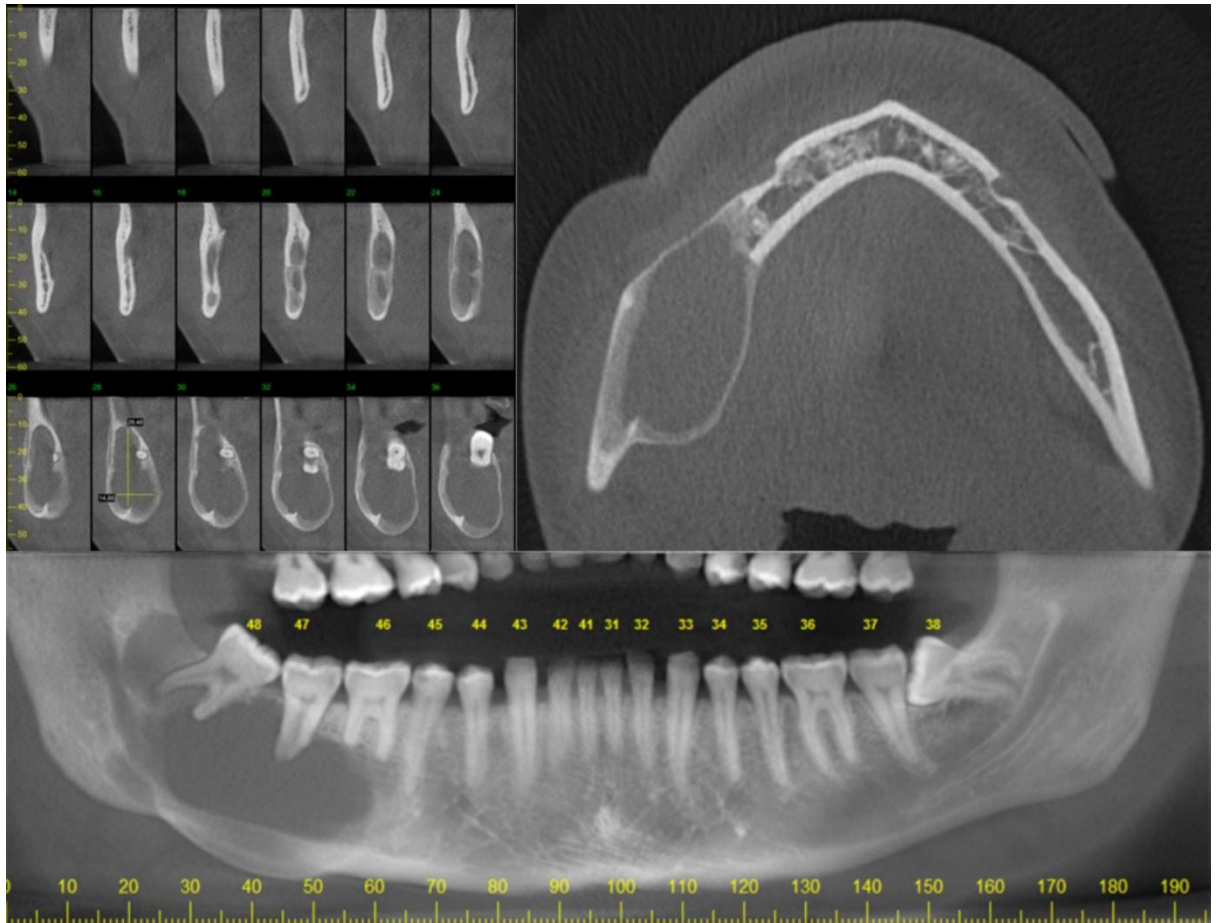


Figure 2. Preoperative CT scan.

An incisional biopsy was performed and the diagnosis of ameloblastoma was confirmed (Figure 3).

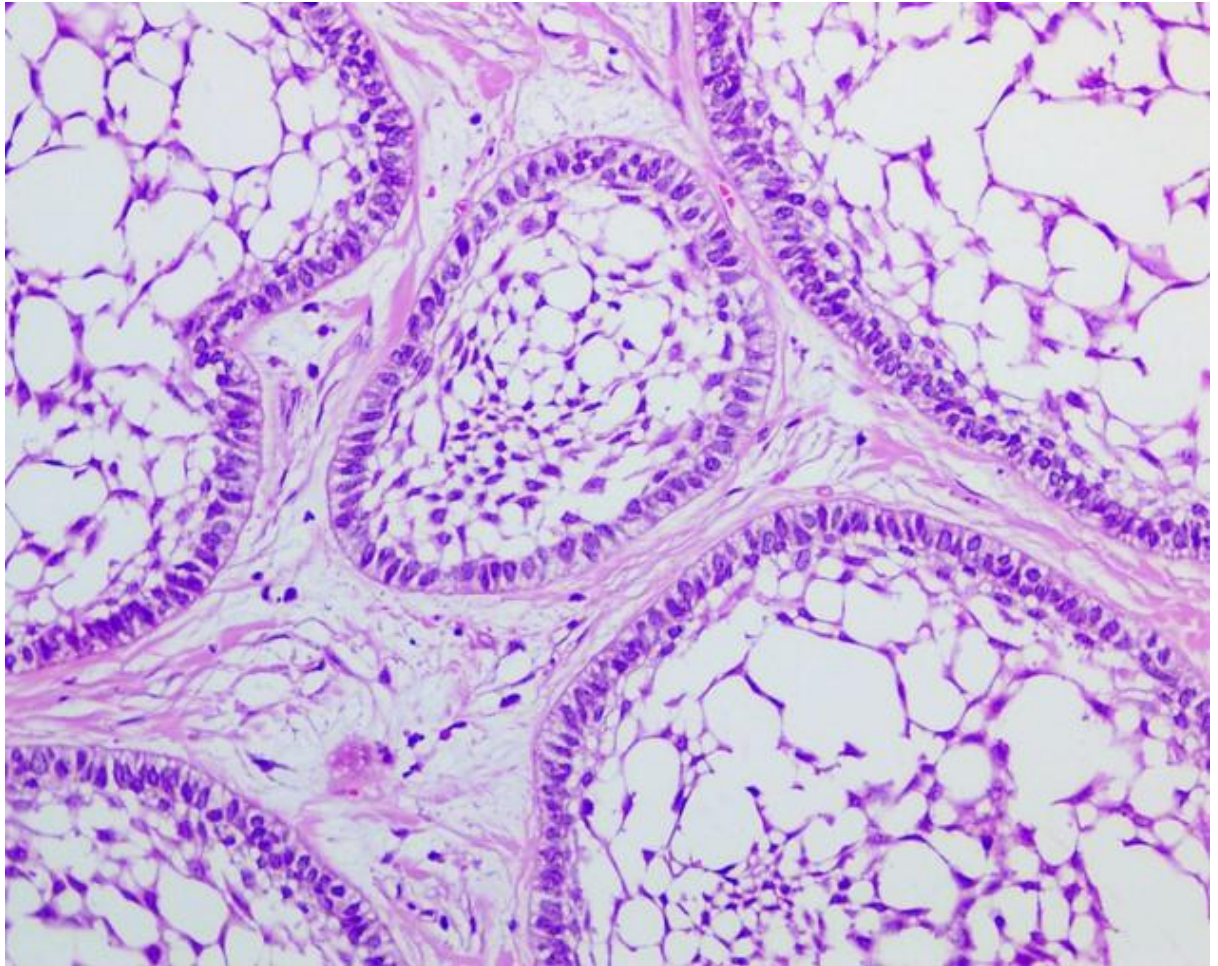


Figure 3. Histopathological features. Islands and strands of ameloblastic epithelium demonstrating loosely arranged cells in the center of the islands and hyperchromatic cells in the periphery. The neoplastic epithelial islands were surrounded by a fibrous stroma.

The primary surgery was performed with a segmental resection of the lesion and placement of a reconstructive bone plate with 2.4mm to mandible contour and space maintenance (Figure 4).

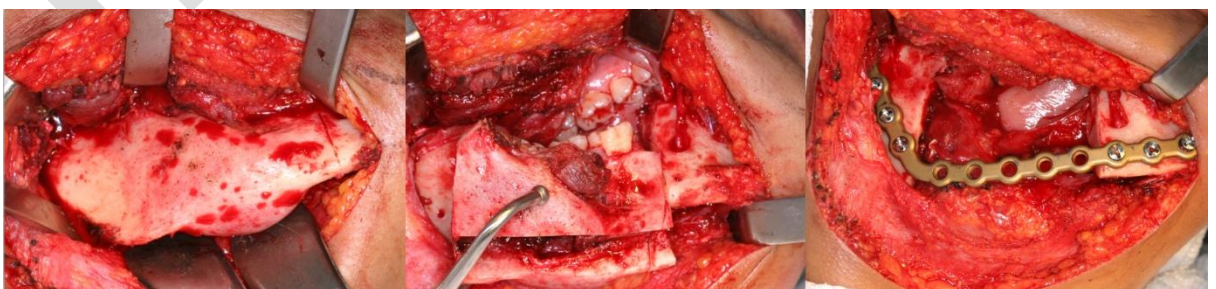


Figure 4. Segmental resection and placement of a reconstructive bone plate was performed in the primary surgery.

20 months later, the secondary reconstruction surgery was performed, using a cutting guide for a precise measurement of the iliac crest graft, developed through virtual planning using the CAD-CAM technology.

The virtual planning was executed together with the *Programa de Tecnologias 3D para Saúde (PROMED)*, offered by the *Centro de Tecnologia da Informação Ricardo Archer*. Medical imaging data in Digital Imaging and Communications in Medicine (DICOM) format obtained from computed tomography were imported into InVesalius software (version 3.1, CTI Renato Archer, Brazil) for segmentation and three-dimensional reconstruction of the skull, mandible, and iliac crest. The segmented anatomical structures were exported in Standard Tessellation Language (STL) format and further processed in Materialise Magics software (version 2021, Materialise NV, Leuven, Belgium), where surface optimization, mandibular mirroring and virtual modeling of the surgical guide were performed. The models were exported as STL files and manufactured using additive manufacturing technology in polyamide (PA12 nylon), resulting in patient-specific anatomical models and surgical guides for intraoperative assistance (Figure 5a-d).

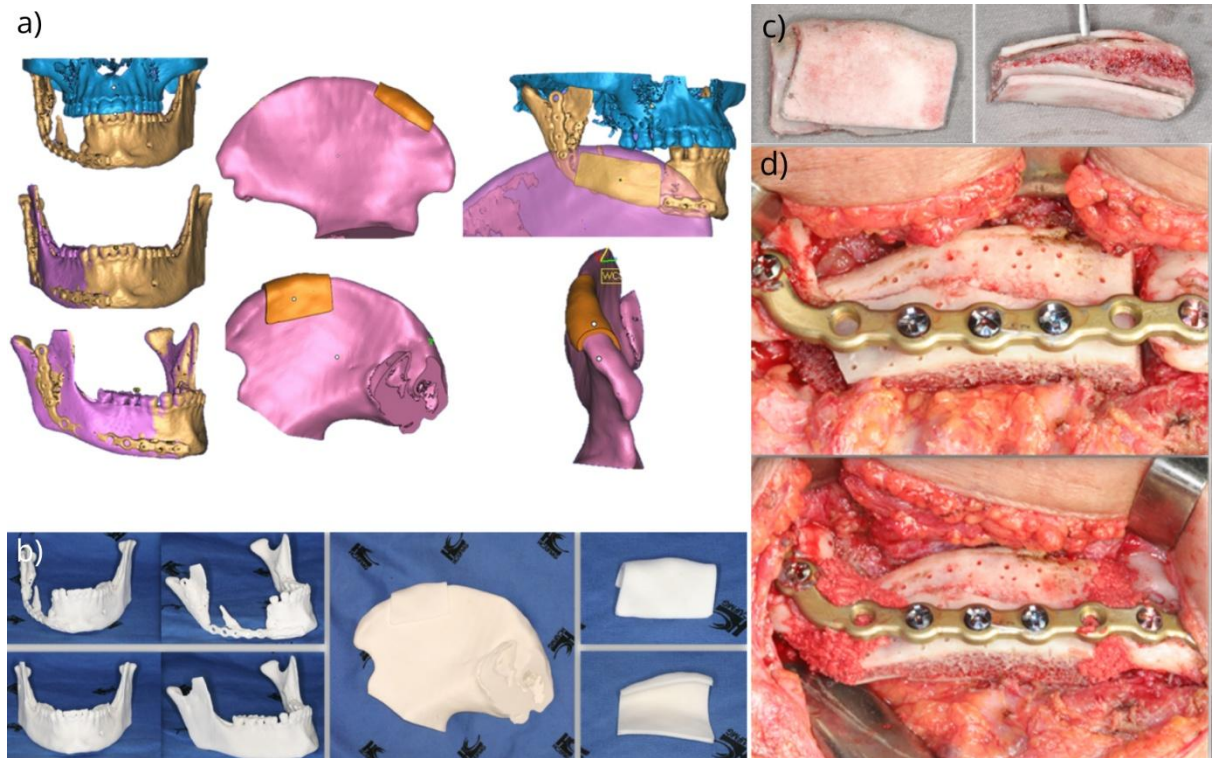


Figure 5. a) Virtual planning of the stereographic models and surgical guide. b) Printed original and mirrored stereographic models, and cutting guide. c) Transoperative photos demonstrating the utilization of cutting guide. d) Graft installation in the secondary surgery.

Finally, 22 months after reconstruction with iliac crest graft was carried out the rehabilitation with titanium implants and an implant-supported prosthesis. The patient is in a 6-years follow-up without signs of recurrence (Figure 6).

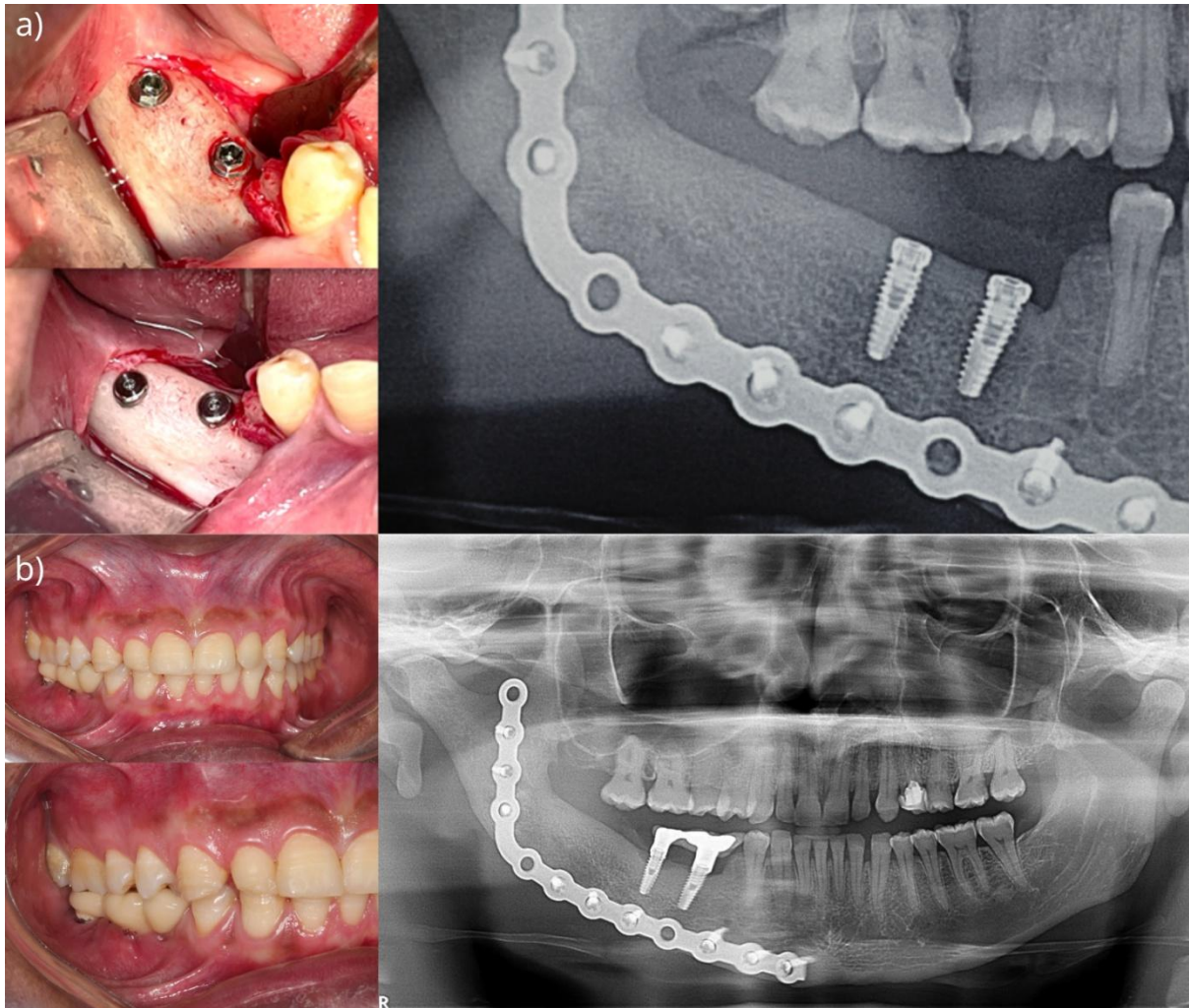


Figure 6. a) Transoperative photos and postoperative panoramic radiography of the installation of two titanium implants. b) Intraoral photos and panoramic radiography after installation of the implant-supported prosthesis.

Discussion

Ameloblastoma is one of the most common benign odontogenic tumors of the jaws, characterized by slow growth, local invasiveness, and a high recurrence rate. It predominantly affects adults between the third and sixth decades of life and most commonly involves the posterior mandible. Slow-growing and painless swelling is the most common presentation of Ameloblastoma. Computed tomography and histopathological analysis are fundamental for diagnosis and assessment of lesion extent^{6,8}.

Surgical management is the modality of choice for conventional ameloblastoma^{1,2,5,6,8}; however, the decision between conservative and radical treatment is determined by tumor size, anatomical location, patient age and sex, and histopathological subtype^{1,6}. In the present case, the patient presented with pain and mandibular involvement. Despite the young age, the lesion was diagnosed as conventional ameloblastoma and showed involvement of the inferior border of the mandible with tooth resorption and extensive bone expansion. Therefore, segmental resection with adequate surgical margins was performed and no recurrence was observed during a six-year follow-up period.

Mandibular defects after tumor resection compromise function and facial aesthetics and require reconstruction⁹. The FFF is the preferred option for extensive defects because of its adequate bone length and reliable vascular pedicle; however, it is associated with limited vertical height^{2,7}, longer operative time, higher costs, and prolonged hospitalization. Non-vascularized bone grafts are indicated for selected cases of benign tumors and limited defects with preserved mandibular continuity⁹. The ICG provides suitable bone volume and mandibular curvature but is not recommended for defects larger than 6 cm due to increased resorption rates⁴. In the present case, an iliac crest graft was chosen because of its adequate bone height and contour and the surgical team's experience with this technique.

CAD–CAM technology has been introduced in orofacial reconstruction to increase surgical precision while reducing morbidity and operative time⁷. Virtual surgical planning (VSP) has demonstrated greater accuracy and shorter total operative time compared with freehand surgery, as well as improved patient outcomes. Nevertheless, the main limitations of CAD–CAM technologies include the high costs associated with VSP and customized implants and the delay between

planning and product delivery. Therefore, pre-bending reconstruction plates on stereolithographic (STL) models may reduce costs, and minimizing the interval between VSP and surgery helps prevent progression of tumor margins^{2,7,10}.

Computer-assisted surgery (CAS) comprises the acquisition of three-dimensional (3D) imaging data from computed tomography, CAD/CAM, and surgical execution with postoperative evaluation¹⁰. CAS enables virtual modeling, mirroring of the healthy mandibular side, definition of resection margins, and simulation of graft osteotomies, as well as the fabrication of STL models and surgical guides^{7,10}. In the present case, this workflow was applied to construct a mirrored mandible and a cutting guide for the ICG, reducing operative time and morbidity by enabling faster and more precise graft harvesting.

Furthermore, CAD/CAM technologies enable immediate placement of dental implants and even implant-supported prostheses in a single surgical procedure, known as the “Jaw-in-a-day” approach. This protocol allows tumor resection, mandibular reconstruction, and prosthetic rehabilitation to be performed in one operative stage, thereby reducing the period without prosthetic function and representing a viable strategy to enhance osseointegration prior to radiotherapy^{10,11}. In our service, resection and reconstruction of benign tumors are performed in two separate stages with an interval of several months. This delay allows complete healing of the oral mucosa and prevents intraoral communication with the graft, thereby reducing the risk of infection and graft failure.

Conclusion

This report demonstrates that CAD–CAM technology enables the fabrication of patient-specific cutting guides and surgical tools that translate virtual planning into

accurate intraoperative execution. This approach improves graft adaptation, enhances surgical predictability, and reduces operative time and morbidity, representing a reliable strategy for mandibular reconstruction after benign tumor resection.

AUTHORS' CONTRIBUTIONS

Willian Gabriell de Matos Araújo Moraes - manuscript writing, revision

Arianne Kimberly Barbosa da Matta - Manuscript writing, revision

Marco Túllio Becheleni Ávila Guimarães - Orientation, revision

Wagner Henriques de Castro - Orientation, revision

CONFLICT OF INTEREST STATEMENT

Funding: The authors declare that no funds, grants, or other support were received during the preparation of this manuscript.

Competing interests: The authors have no relevant financial or non-financial interests to disclose.

Ethics approval: Informed consent was obtained from the patient.

References

1. Saghravanian N, Salehinejad J, Ghazi N, Shirdel M, Razi M. A 40-year Retrospective Clinicopathological Study of Ameloblastoma in Iran. *Asian Pac J Cancer Prev.* 2016; 17(2), 619-23.
2. Abbate V, Togo G, Committeri U, Zarone F, Sammartino G, Valletta A, et al. Full digital workflow for Mandibular Ameloblastoma management: showcase for technical description. *Journal of Clinical Medicine.* 2023;12(17):5526.
3. Silva CC, Perrelli MC, Araújo e Silva ME, Gonçalves KK, Diniz DA, Carneiro SC. Reconstrução mandibular com enxerto livre de crista ilíaca: relato de caso. *Odontol. Clín.-Cient.* 2021;20(3):88-92.
4. Barros MAN, Teslenco VB, Reis GN, Pancini EF, Cavalcanti H de A. Enxerto ósseo autógeno de crista ilíaca para tratamento de defeito mandibular. *Archives of Health Investigation.* 2021;10(4):615–8.
5. Srivastava G, Padhiary SK, Nayak TK, Mishra N. Rehabilitation using implants in free fibula flap of a patient with ameloblastoma: Case report with

- 4-year follow-up. *National Journal of Maxillofacial Surgery*. 2022;13(Suppl 1):S194-8.
6. Ghai S. Ameloblastoma: an updated narrative review of an enigmatic tumor. *Cureus*. 2022;14(8):e27734.
7. Tarsitano A, Mazzoni S, Cipriani R, Scotti R, Marchetti C, Ciocca L. The CAD-CAM technique for mandibular reconstruction: An 18 patients oncological case-series. *Journal of Cranio-Maxillofacial Surgery*. 2014;42(7):1460–4.
8. Alarcón-Sánchez MA, Becerra-Ruiz JS, Yessayan L, Mosaddad SA, Heboyan A. Implant-supported prosthetic rehabilitation after Ameloblastomas treatment: a systematic. 2023;23(1):1013.
9. Moura LB, Carvalho PHA, Xavier CB, Post LK, Torriani MA, Santagata M et al. Autogenous non-vascularized bone graft in segmental mandibular reconstruction: a systematic review. *Int J Oral Maxillofac Surg*. 2016;45(11):1388-94.
10. Probst FA, Liokatis P, Mast G, Ehrenfeld M. Virtual planning for mandible resection and reconstruction. *Innovative Surgical Sciences*. 2023;8(3):137-48.
11. Kang YF, Ge YJ, Lv XM, Ding MK, Shan XF, Cai ZG. One-stage jaw reconstruction and prosthetic rehabilitation with an iliac flap: a case report and literature review. *Maxillofacial Plastic and Reconstructive Surgery*. 2024;46(1):3.

In Press