









Marco Tulio Leandro Ribeiro<sup>1</sup>   
 Fábio Ramoa Pires<sup>2</sup>   
 Rogério de Andrade Elias<sup>1</sup>   
 Fábio de Abreu Alves<sup>3</sup>   
 Alan Roger Santos-Silva<sup>1</sup>   
 Pablo Agustin Vargas<sup>1</sup>   
 Luiz Paulo Kowalski<sup>4,5</sup>   
 Márcio Ajudarte Lopes<sup>1\*</sup> 

# Oral squamous cell carcinoma adjacent to dental implant: a case report with a long-term follow-up

## Abstract:

Head and neck cancers are a growing global health concern, with oral squamous cell carcinoma (OSCC) accounting for 90–95% of all cases within this region. OSCC near dental implants can resemble benign inflammatory lesions, posing diagnosis challenging. A 74-year-old man presented with an ulcerated, asymptomatic lesion in the upper right alveolar mucosa, initially misdiagnosed as a benign inflammatory condition due to its proximity to a dental implant. Afterwards the lesion was identified as OSCC, and the patient underwent surgical treatment. Three years post-surgery, a white plaque appeared near the grafted area and was diagnosed as oral leukoplakia. Although, over the course of fourteen years, the patient had no recurrences or metastases. Therefore, clinicians should be aware that while most lesions around dental implants are of inflammatory origin, OSCC must be considered in differential diagnosis in cases that do not respond to standard treatments.

**Key words:** Oral squamous cell carcinoma; Dental implants; Oral Cancer; Oral Pathology.

## INTRODUCTION

Head and neck cancers are a group of diseases that represents a global health concern due to its high prevalence, incidence, morbidity, and mortality<sup>1</sup>. Oral squamous cell carcinoma (OSCC) is the most common subtype in this anatomical region, accounting for around 90–95% of all cases<sup>1,2</sup>.

The main risk factors for OSCC development are the use of harmful substances such as tobacco and alcohol, which act in a synergistically way in the context of carcinogenesis<sup>3</sup>. However, other genetic and

epigenetic aspects, such as mutations, deregulation in the expression of tumor suppressor genes, proto-oncogenes, and DNA methylation, can also play an important role in the onset and progression of the disease<sup>4-6</sup>.

In the oral cavity, squamous cell carcinoma (SCC) can manifest in different areas, mostly affecting the lateral border of the tongue, floor of the mouth, and gingiva/alveolar mucosa<sup>7</sup>. Gingival SCC have the potential to mimic benign inflammatory lesions such as gingivitis,

periodontal disease, pyogenic granuloma, and inflammatory fibrous hyperplasia<sup>8,9</sup>.

### Statement of Clinical Significance

Oral squamous cell carcinoma (OSCC) near dental implants can resemble benign peri-implant conditions, resulting in diagnostic challenges and potential delays. This case report provides a clear overview of OSCC presentation and characteristics, helping clinicians differentiate these lesions. As dental implants become increasingly common, recognizing OSCC in non-responsive peri-implant lesions is vital for timely intervention and enhanced patient care.

<sup>1</sup>University of Campinas, Piracicaba Dental School, Department of Oral Diagnosis – Piracicaba (SP), Brazil.

<sup>2</sup>Rio de Janeiro State University, School of Dentistry, Department of Diagnosis and Surgery, Oral Pathology – Rio de Janeiro (RJ), Brazil.

<sup>3</sup>A.C. Camargo Cancer Center, Department of Oral Medicine – São Paulo (SP), Brazil.

<sup>4</sup>A.C. Camargo Cancer Center, Department of Head and Neck and Otorhinolaryngology Surgery – São Paulo (SP), Brazil.

<sup>5</sup>University of São Paulo Medical School, Head and Neck Surgery Department – São Paulo (SP), Brazil.

\*Correspondence to: Email: malopes@fop.unicamp.br

Received on October 4, 2024. Accepted on November 26, 2024

<https://doi.org/10.5327/2525-5711.267>



OSCC can be eventually located in the tissues around osseointegrated dental implants<sup>10</sup>. The presence of alterations with reactive appearance close to these areas, may be associated with traumatic events or peri-implant diseases, turning the early diagnosis of peri-implant OSCC a challenging issue<sup>9,11</sup>.

Here, we report an additional case of an OSCC in the upper right alveolar mucosa adjacent to a dental implant.

### CASE REPORT

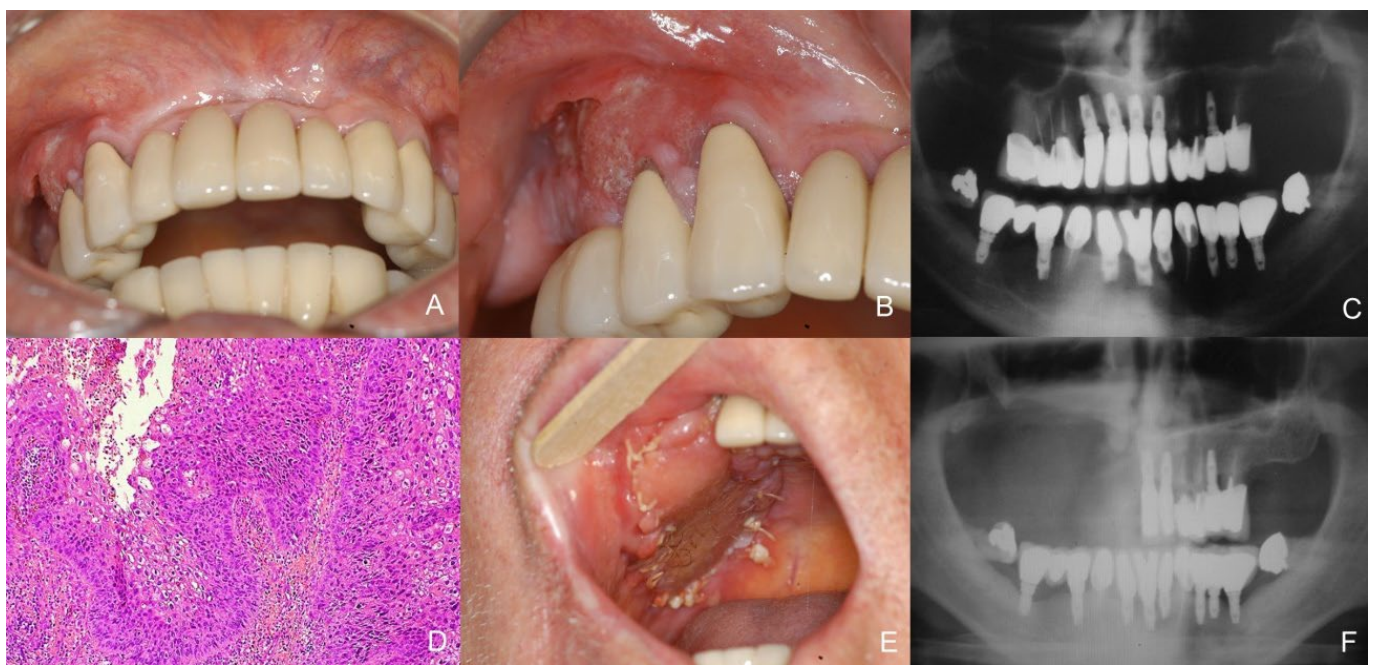
A 74-year-old male was referred by a general dentist for evaluation of a lesion in the posterior region of the right maxilla, with approximately four months of evolution. The patient reported to be a former tobacco and alcohol user, with no underlying medical conditions. The patient also informed that he was undergoing prosthetic rehabilitation with dental implant, and about a month after the surgery for placement of the implant, experienced bleeding near the surgical site. Three months later, the dentist identified an ulceration in the area that was managed using topical steroids and antivirals. As there was no clinical response, the patient was then referred to an Oral Medicine service.

On clinical examination, a solitary 1.5 cm ulcerated lesion was observed in the right posterior maxillary

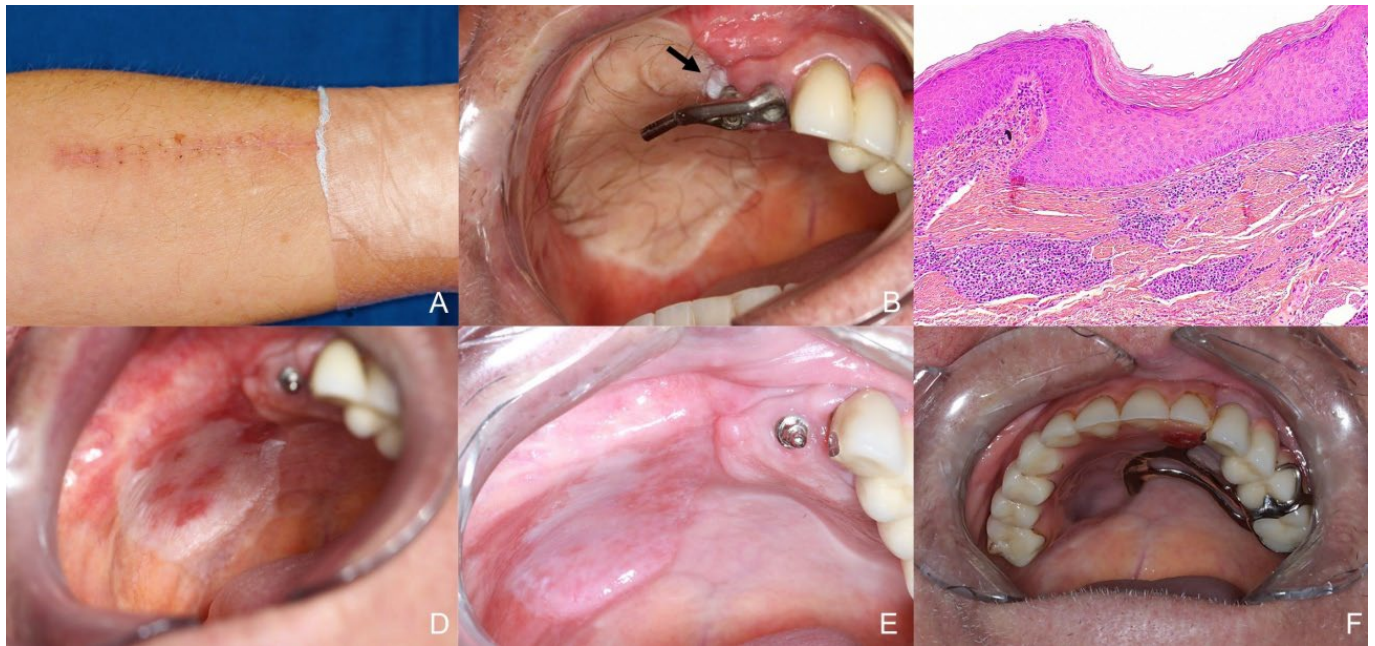
gingiva and alveolar mucosa adjacent to fixed prostheses and dental implant (Figures 1A and 1B). No palpable lymphadenopathy was observed upon examination of the cervical region. An orthopantomography was requested, and the analysis of the images disclosed an absence of relevant alterations in the osseous framework (Figure 1C). Under the clinical suspicion of OSCC, an incisional biopsy was performed. Histopathological examination revealed a fragment of oral mucosa covered by stratified squamous epithelium, showing nests and cords of pleomorphic and atypical epithelial cells invading the underlying connective tissue, confirming the diagnosis of OSCC (Figure 1D).

The patient was subsequently referred for oncologic treatment. Surgical resection, encompassing the superficial right maxillary bone and adjacent soft tissues, along with supra-omohyoid neck dissection, was performed (Figures 1E and 1F). Histopathological analysis of the surgical specimen showed clear margins, absence of perineural invasion and angiolymphatic invasion, and absence of lymph node metastasis, being the tumor classified as pT1N0M0. The surgical defect was reconstructed using a microsurgical skin graft harvested from the patient's left forearm (Figure 2A).

Initially, postoperative follow-up evaluations occurred every three months in the first year, during



**Figure 1.** A and B) Initial clinical appearance showing the presence of an ulcerated lesion in the upper right gingiva/alveolar mucosa, close to fixed prostheses and dental implant. C) Initial orthopantomography did not present relevant bone lesion D) Histopathological features showing proliferation of neoplastic squamous cells, invading the connective tissue (H&E, 10x). E) One-month postoperative follow-up. F) Postoperative orthopantomography.



**Figure 2.** A) Graft donor site – left forearm. B) Three years postoperative follow-up displaying a 3mm white plaque around the skin graft. C) Histopathological features showing hyperkeratosis, acanthosis, and inflammatory infiltrate in the fibrous connective tissue (H&E 10x). D) Grafted tissue in process of adaptation in the resected area. E) Appearance of the area at the last follow-up, fourteen years after the surgical treatment. F) Appearance of the area with the prostheses at the last follow-up.

which the patient underwent rehabilitation with new implant-supported prostheses. Subsequently, the frequency of follow-ups became annual, and in the third year, a 3 mm well-defined white homogeneous plaque was observed around the grafted area (Figure 2B). An excisional biopsy was performed, and histopathological examination showed hyperkeratosis and acanthosis compatible with the clinical diagnosis of oral leukoplakia (Figure 2C). The patient remains in follow-up for 14 years without any evidence of recurrences or metastases (Figures 2D, 2E and 2F).

## DISCUSSION

OSCC stands as the most prevalent cancer in the head and neck region, with an estimated global incidence of approximately 476,125 new cases and 225,900 deaths annually. In the specific context of Brazil, it accounts for around 15,140 new cases each year, with approximately 7,440 associated deaths<sup>12,13</sup>.

OSCC is an aggressive malignant neoplasm of epithelial origin, characterized by a wide range of clinical presentations, from the initial presence of white and/or red patches to large tumors and metastases in more advanced stages<sup>8,9,14</sup>. The literature indicates that a considerable number of these carcinomas are preceded

by oral potentially malignant disorders (OPMD); nevertheless, most appear to arise “*de novo*”, developing from normal-appearing mucosa without prior OPMD involvement<sup>15</sup>. This pattern is observed in approximately 81% of all cases, creating substantial obstacles for cancer screening and early detection, as it lacks visible changes in initial stages<sup>15,16</sup>.

OSCC predominantly affects men over the age of 50 with a history of tobacco and alcohol chronic use, and it has the potential to emerge in different sites in the oral cavity, most commonly the borders of tongue and floor of the mouth<sup>9</sup>. Intriguingly, when it affects the gingiva and alveolar mucosa, the tumor shows a marked predilection for females and displays a less frequent association with tobacco consumption<sup>9,17</sup>. In the present case, the patient aligns with the general epidemiological profile reported for OSCC; however, this case contrasts with trends reported specifically for gingival and alveolar mucosa tumors.

Another noteworthy aspect is that early-stage gingival/alveolar mucosal SCC often resembles a wide range of benign inflammatory lesions, posing a diagnostic challenge even for experienced clinicians<sup>18</sup>. In this case, the lesion was initially misdiagnosed as a peri-implant reactive lesion, likely due to its proximity to a recently placed dental implant, which delayed diagnosis and impacted the outcome.



---

Although the OSCC pathogenetic mechanism is not fully understood, it is widely accepted as a multi-step process<sup>18</sup>. Chronic exposure to tobacco and alcohol, especially in combination, is the primary factor driving OSCC development due to their proven synergistic effect in carcinogenesis. Other etiological factors that may play a role in the onset of the disease include nutritional and vitamin deficiencies, genetic predisposition, and immunosuppression. Chronic inflammation, and prolonged exposure to metallic dental materials have been also suggested, although this latter factor remains controversial among researchers<sup>17-19</sup>. In this case, the patient was exposed to major risk factors, as he reported being a former tobacco and alcohol user, and the lesion developed in an area adjacent to a titanium dental implant, allowing to correlate with possible risks mentioned in the literature.

Since their inception, titanium implants have evolved into a feasible and relatively safe option for dental rehabilitation and are now widely recognized as the gold standard, becoming increasingly common in clinical practice<sup>20</sup>. Given the widespread use of dental implants, understanding the interactions between metallic compounds and cellular effects is essential, as the incidence of implant-related OSCC may increase in the coming years<sup>21,22</sup>.

In this context, several studies have explored the potential link between metal exposure and OSCC development<sup>19,23</sup>. Ortiz et al. reported that metals like titanium and stainless-steel alloys may cause DNA damage through immunomodulatory and mutagenic effects by leaching ions and nanoparticles into surrounding tissues<sup>19</sup>. In a later study focused on titanium dental implants, Del Amo et al. suggested that titanium particles released into peri-implant tissues can trigger an inflammatory response, exacerbate cellular injury and oxidative stress in oral epithelial cells, disrupt homeostasis, and weaken epithelial barrier integrity. Additionally, they found that titanium contributes to oncogenesis by impairing the activation of tumor suppressor genes, such as BRCA1 and CHK2, both markers associated with tumor initiation and progression<sup>23</sup>.

The placement of dental implants in regions adjacent to areas with OPMD is contraindicated<sup>24</sup>. OSCC that arises near titanium implants often develops from apparently normal mucosa, following a “*de novo*” pattern. Clinically, these carcinomas differ from those originating in regions with the presence of an OPMD, as they do not present a precursor lesion.

Additionally, they are typically larger, with greater ulceration and painful symptoms, and are more frequently associated with local and distant metastases compared to others<sup>15</sup>. The literature suggests that these “*de novo*” tumors may result from a phenomenon known as field change (FC), characterized by widespread genetic alterations in the oral mucosa, which increase the likelihood of carcinoma development at multiple sites<sup>15,25</sup>.

In areas adjacent to dental implants, the formation of these FC is promoted by chronic inflammation caused by the presence of titanium, which induces genetic changes that make the mucosal surface more susceptible to cancer<sup>23</sup>. A significant clinical implication is that mutated cell fields often remain after the resection of the primary tumor, heightening the risk of local recurrence or even the development of a second primary tumor in another area. This requires clinicians to be vigilant for the early recognition of possible tissue changes<sup>26</sup>.

In the present case, post-treatment follow-up revealed a whitish plaque resembling leukoplakia on the oral mucosa, indicating significant tissue changes that support the FC hypothesis. However, despite these findings, the studies on the development of OSCC associated with the presence of titanium in the oral mucosa are still scarcely addressed and were unable to provide definitive conclusions to support this relationship.

Concerning the treatment of gingival/alveolar mucosal carcinomas, the approach depends on the degree of involvement of the adjacent structures<sup>27</sup>. As reported by Bark et al., the preferred treatment modality for these cases involves surgical resection with free margins, tissue reconstruction, and, in indicated cases, adjuvant radiotherapy, depending on the stage of the lesion. Gingival tumors are usually more aggressive, mostly affecting and destroying surrounding bone framework. This is attributed to their insidious initial appearance, often resulting in a late diagnosis, and the close contact of the gingival tissue and the periosteum in the region, increasing the risk of regional and distant metastases, especially in the mandible<sup>17,27</sup>. In the current case, the patient underwent resection of the affected superficial bone of the right maxilla, followed by reconstruction with a graft obtained from the left forearm. Adjuvant therapies were not indicated since there were free surgical margins and no regional metastasis.

Regarding survival, patients with SCC affecting gingiva or alveolar mucosa generally have a poorer prognosis compared to those with OSCC in other oral regions. Gingival lesions have a 5-year survival rate

of about 43%, while lesions in other regions have a rate of around 64%<sup>27-29</sup>. In this case, despite the patient presenting tissue changes during follow-up, he has been disease-free for fourteen years post-treatment.

## CONCLUSION

In summary, OSCC arising in areas adjacent to dental implants presents a potential challenge, as it may mimic benign inflammatory lesions and peri-implantitis. Therefore, it is important to consider OSCC in the differential diagnosis of lesions associated with dental implants that do not respond to conventional treatments.

## AUTHORS' CONTRIBUTIONS

MTLR: conceptualization, data curation, formal analysis, visualization, writing –original draft, writing – review & editing. FRP: supervision, writing – review & editing. RAE: methodology, writing – review & editing. FAA: methodology, writing – review & editing. ARSS: methodology, writing – review & editing. PAV: methodology, writing – review & editing. LPK: methodology, writing – review & editing. MAL: conceptualization, project administration, supervision, writing –original draft, writing – review & editing.

## CONFLICT OF INTEREST STATEMENT

**Funding:** This study was partially funded by the Brazilian government research agency, "Coordenação de Aperfeiçoamento de Pessoal de Nível Superior (CAPES)", under Finance Code 001.

**Competing interests:** The authors have no relevant financial or non-financial interests to disclose.

**Ethics approval:** Not applicable.

## REFERENCES

1. Badwelan M, Muaddi H, Ahmed A, Lee KT, Tran SD. Oral squamous cell carcinoma and concomitant primary tumors, what do we know? A review of the literature. *Curr Oncol*. 2023;30(4):3721-34. <https://doi.org/10.3390/curroncol30040283>
2. Varsha BK, Radhika MB, Makarla S, Kuriakose MA, Kiran GS, Padmalatha GV. Perineural invasion in oral squamous cell carcinoma: case series and review of literature. *J Oral Maxillofac Pathol*. 2015;19(3):335-41. <https://doi.org/10.4103/0973-029X.174630>
3. Mello FW, Melo G, Pasetto JJ, Silva CAB, Warnakulasuriya S, Rivero ERC. The synergistic effect of tobacco and alcohol consumption on oral squamous cell carcinoma: a systematic review and meta-analysis. *Clin Oral Investig*. 2019;23(7):2849-59. <https://doi.org/10.1007/s00784-019-02958-1>
4. Ghantous Y, Schussel JL, Brait M. Tobacco and alcohol-induced epigenetic changes in oral carcinoma. *Curr Opin Oncol*. 2018;30(3):152-8. <https://doi.org/10.1097/CCO.0000000000000444>
5. Ali J, Sabiha B, Jan HU, Haider SA, Khan AA, Ali SS. Genetic etiology of oral cancer. *Oral Oncol*. 2017;70:23-8. <https://doi.org/10.1016/j.oraloncology.2017.05.004>
6. Irimie AI, Ciocan C, Gulei D, Mehterov N, Atanasov AG, Ducea D, et al. Current insights into oral cancer epigenetics. *Int J Mol Sci*. 2018;19(3):670. <https://doi.org/10.3390/ijms19030670>
7. Badwelan M, Muaddi H, Ahmed A, Lee KT, Tran SD. Oral squamous cell carcinoma and concomitant primary tumors, what do we know? A review of the literature. *Curr Oncol*. 2023;30(4):3721-34. <https://doi.org/10.3390/curroncol30040283>
8. Pires FR, Ramos AB, Oliveira JBC, Tavares AS, Luz PS, Santos TCRB. Oral squamous cell carcinoma: clinicopathological features from 346 cases from a single oral pathology service during an 8-year period. *J Appl Oral Sci*. 2013;21(5):460-7. <https://doi.org/10.1590/1679-775720130317>
9. Chi AC. Epithelial pathology – squamous cell carcinoma. In: Neville BW, Damm DD, Allen CM, Chi AC, editors. *Oral & maxillofacial pathology*. 4th ed. Philadelphia: WB Saunders; 2015. p. 374-89.
10. Raiser V, Abu-El Naaj I, Shlomi B, Fliss DM, Kaplan I. Primary oral malignancy imitating peri-implantitis. *J Oral Maxillofac Surg*. 2016;74(7):1383-90. <https://doi.org/10.1016/j.joms.2016.02.008>
11. Galvis MM, Faustino ISP, Ramos JC, Silva ARS, Alves FA, Kowalski LP, et al. Oral cancer adjacent to dental implants mimicking benign lesions: a case series study. *Aust Dent J*. 2021;66(1):112-8. <https://doi.org/10.1111/adj.12793>
12. International Agency for Research on Cancer. World Health Organization. Cancer today. Data visualization tools for exploring the global cancer burden in 2022 [accessed Jan. 03, 2023]. Available from: <https://gco.iarc.fr/today>
13. Louredo BVR, Curado MP, Penafort PVM, Arruda JAA, Abreu LG, Mesquita RA, et al. Contribution of public oral pathology services to the diagnosis of oral and oropharyngeal cancer in Brazil. *Braz Oral Res*. 2023;37:e126. <https://doi.org/10.1590/1807-3107bor-2023.vol37.0126>
14. Lorini L, Atín CB, Thavaraj S, Müller-Richter U, Ferranti MA, Romero JP, et al. Overview of oral potentially malignant disorders: from risk factors to specific therapies. *Cancers (Basel)*. 2021;13(15):3696. <https://doi.org/10.3390/cancers13153696>
15. Piemonte ED, Gilligan GM, Garola F, Lazos JP, Panico RL, Normando AGC, et al. Differences among oral carcinomas arising de novo from those associated with oral potentially malignant disorders: a systematic review and meta-analysis. *Oral Surg Oral Med Oral Pathol Oral Radiol*. 2024;137(6):613-31. <https://doi.org/10.1016/j.oooo.2024.03.006>
16. Gilligan G, Panico R, Lazos J, Morelato R, Belardinelli P, Criscuolo MI, et al. Oral squamous cell carcinomas and oral potentially malignant disorders: a Latin American study. *Oral Dis*. 2024;30(5):2965-84. <https://doi.org/10.1111/odi.14778>
17. Bharanidharan R, Dineshkumar T, Raghavendhar K, Kumar AR. Squamous cell carcinoma of the gingiva: a diagnostic enigma. *J Oral Maxillofac Pathol*. 2015;19(2):267. <https://doi.org/10.4103/0973-029X.164558>

- 
18. Ramos JC, Alves FA, Kowalski LP, Dos Santos-Silva AR, Vargas PA, Lopes MA. Epidemiological profile and clinical implications of oral squamous cell carcinoma adjacent to dental implants. *Oral Dis.* 2021;27(7):1687-98. <https://doi.org/10.1111/odi.13710>
  19. Ortiz AJ, Fernández E, Vicente A, Calvo JL, Ortiz C. Metallic ions released from stainless steel, nickel-free, and titanium orthodontic alloys: toxicity and DNA damage. *Am J Orthod Dentofacial Orthop.* 2011;140(3):e115-22. <https://doi.org/10.1016/j.ajodo.2011.02.021>
  20. Guillaume B. Dental implants: a review. *Morphologie.* 2016;100(331):189-98. <https://doi.org/10.1016/j.morpho.2016.02.00>
  21. Schache A, Thavaraj S, Kalavrezos N. Osseointegrated implants: a potential route of entry for squamous cell carcinoma of the mandible. *Br J Oral Maxillofac Surg.* 2008;46(5):397-9. <https://doi.org/10.1016/j.bjoms.2007.09.009>
  22. Ramos JC, Dos Santos ES, Normando AGC, Alves FA, Kowalski LP, Santos-Silva AR, et al. Oral squamous cell carcinoma around dental implants: a systematic review. *Oral Surg Oral Med Oral Pathol Oral Radiol.* 2021;131(6):660-74. <https://doi.org/10.1016/j.oooo.2021.01.019>
  23. Del Amo FSL, Rudek I, Wagner VP, Martins MD, O'Valle F, Galindo-Moreno P, et al. Titanium activates the DNA damage response pathway in oral epithelial cells: a pilot study. *Int J Oral Maxillofac Implants.* 2017;32(6):1413-20. <https://doi.org/10.11607/jomi.6077>
  24. Kullar AS, Miller CS. Are there contraindications for placing dental implants? *Dent Clin North Am.* 2019;63(3):345-62. <https://doi.org/10.1016/j.cden.2019.02.004>
  25. Peralta-Mamani M, Terrero-Pérez Á, Tucunduva RMA, Rubira CMF, Santos PSS, Honório HM, et al. Occurrence of field cancerization in clinically normal oral mucosa: a systematic review and meta-analysis. *Arch Oral Biol.* 2022;143:105544. <https://doi.org/10.1016/j.archoralbio.2022.105544>
  26. Dakubo GD, Jakupciak JP, Birch-Machin MA, Parr RL. Clinical implications and utility of field cancerization. *Cancer Cell Int.* 2007;7:2. <https://doi.org/10.1186/1475-2867-7-2>
  27. Bark R, Mercke C, Munck-Wikland E, Wisniewski NA, Hammarstedt-Nordenvall L. Cancer of the gingiva. *Eur Arch Otorhinolaryngol.* 2016;273(6):1335-45. <https://doi.org/10.1007/s00405-015-3516-x>
  28. Arduino PG, Carbone M, Gambino A, Cabras M, Cannarsa F, Macciotta A, et al. Challenging management of gingival squamous cell carcinoma: a 10 years single-center retrospective study on Northern-Italian patients. *Med Oral Patol Oral Cir Bucal.* 2021;26(1):e21-e27. <https://doi.org/10.4317/medoral.23913>
  29. Sim YC, Hwang JH, Ahn KM. Overall and disease-specific survival outcomes following primary surgery for oral squamous cell carcinoma: analysis of consecutive 67 patients. *J Korean Assoc Oral Maxillofac Surg.* 2019;45(2):83-90. <https://doi.org/10.5125/jkaoms.2019.45.2.83>